



**PATIENT PRESENTING CLINICAL SIGNS**

**Nala Nisbett** History: Vomited 5-6 times yesterday and no vomiting today as per owner. Abdomen is bloated need to rule out foreign body vs others.

**SPECIES RADIOGRAPHIC STUDY OF THE ABDOMEN**

**Feline** The body condition score is 7/9 with a rather large amount of intraabdominal fat. The mammary gland region appears altered on one lateral view only.

**BREED** New bone formation is present on the femoral heads, right more than left.

**DSH** The abdominal detail is good; diaphragm and abdominal wall are intact.

The liver is located within the costal arch and the caudo-ventral lobe is pointed.

**SEX** The spleen appears physiological.

**Female** The stomach is empty; distribution and size of the small intestinal loops appear physiological. Colon and rectum contain a moderate amount of gas.

**AGE** Both renal shadows have a physiological size, shape and opacity; the surfaces are smooth. The bladder is located in the abdominal cavity and contains a moderate amount of homogeneous fluid opacity.

A tubular, soft tissue structure between colon and bladder extends cranially into the convoluted loops of small intestine.

**INTERPRETED BY**

**Heike Rudolf, DVM, Dr. med. Vet., DipECVDI DVR** The sublumbar region appears physiological.

**RADIOGRAPHIC DIAGNOSIS**

**HOSPITAL NAME**

- Uterine enlargement
- Possible mammary gland enlargement
- Bilateral hip arthrosis (incidental finding)

Truscott AH

**INTERPRETATION OF THE FINDINGS & FURTHER RECOMMENDATIONS**

**REFERRING VET**

**Dr. Medhat Meawad**

Abdominal ultrasound is recommended to rule out uterine enlargement due to pyometra, hemometra or early pregnancy. Blood should be submitted for hematology and full biochemistry if it has not already been done. The bloated appearance on clinical examination could be due to the combination of intraabdominal fat and gas in the large intestine. The altered appearance of the mammary tissue could represent an artefact due to superimpositioning, but visual inspection and palpation are recommended

**INVOICE**

20309

**DATE**

12/30/22



**PATIENT**

Nala Nisbett

**SPECIES**

Feline

**BREED**

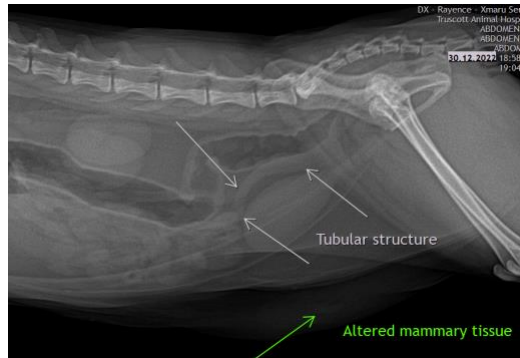
DSH

**SEX**

Female

**AGE**

2 Years



**The information and recommendations provided are based on the images presented by the referring veterinarian/sonographer. No evaluation can be communicated regarding pathology that was not visible in the image/video clips provided.**

Thank you for this referral. If the clinical or image interpretation does not parallel your findings or if I can be of any further assistance please contact me.

**Heike Rudolf**, DVM, Dr. med. vet., DipECVDI, DVR  
dr.h.rudorf@gmail.com

**INTERPRETED BY**

Heike Rudolf, DVM,  
Dr. med. Vet.,  
DipECVDI DVR

**HOSPITAL NAME**

Truscott AH

**REFERRING VET**

Dr. Medhat Meawad

**INVOICE**

20309

**DATE**

12/30/22